



zimmer
dental

Clinical Case Studies
COPIOS EXTEND™
MEMBRANES

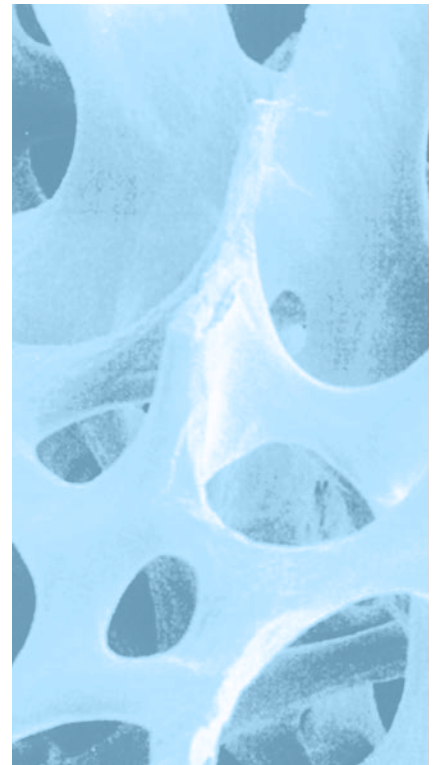




TABLE OF CONTENTS

CopiOs Extend™ Membranes

CASE 1 *CopiOs Extend* Membrane with Puros® Cortico-Cancellous Allograft: Maxillary Molar

CASE 2 *CopiOs Extend* Membrane with Puros DBM Putty with Chips: Mandibular Molar

CASE 3 *CopiOs Extend* Membrane with Puros DBM Putty with Chips: Maxillary Molar

CASE 4 *CopiOs Extend* Membrane with Puros Cortico-Cancellous Allograft: Maxillary Molar

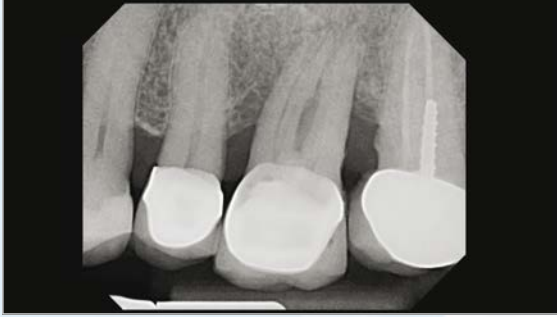CASE 5 *CopiOs Extend* Membrane with Puros DBM Putty with Chips: Mandibular Molar

Clinical photographs courtesy of Edgard El Chaar, D.D.S, M.S.,
New York, NY, USA. All rights reserved. Individual results may vary.

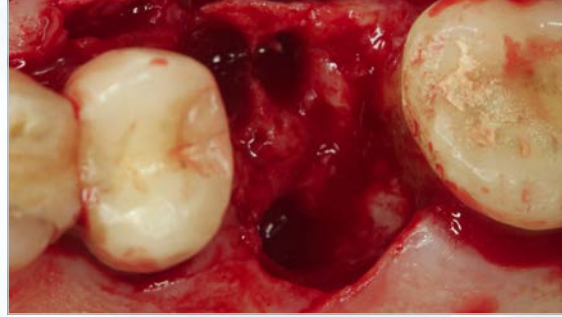


Disclaimer.

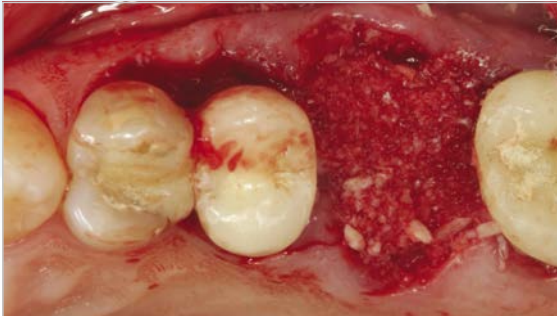
This documentation is intended exclusively for physicians and dentists and is not intended for laypersons. Information on the products and procedures contained in this document is of a general nature and does not represent and does not constitute medical advice or recommendations. Because this information does not purport to constitute any diagnostic or therapeutic statement with regard to any individual medical case, each patient must be examined and advised individually, and this document does not replace the need for such examination and/or advice in whole or in part. Please refer to the package inserts for important product information, including, but not limited to, contraindications, warnings, precautions and adverse effects.

CASE #1:**CopiOs Extend Membrane with Puros Cortico-Cancellous Allograft: Maxillary Molar**

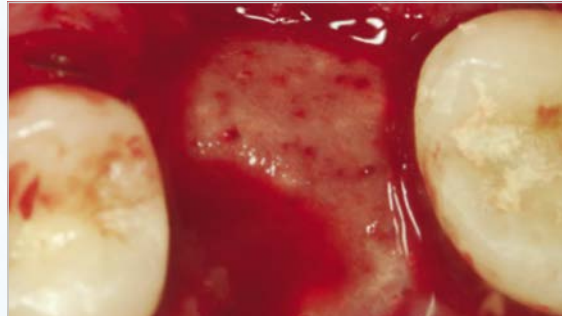
1 Pre-operative radiograph showing the poor periodontal prognosis of 1st molar and bone loss on mesial of the 2nd molar.



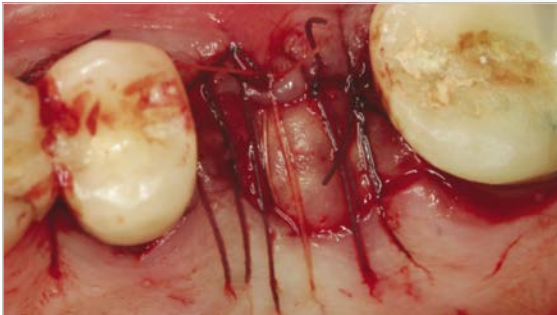
2 View of the extraction socket revealing the extent of bone loss on the mesial of the 2nd molar.



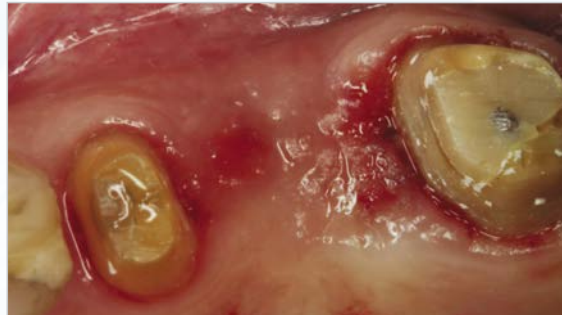3 *Puros Cortico-Cancellous Allograft* placed in the socket.



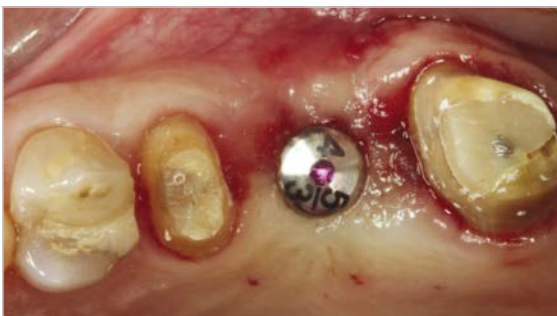4 *CopiOs Extend Membrane* tucked under the flap and laid over the graft.



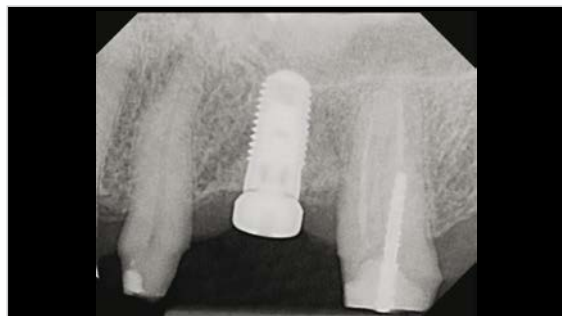5 Sutures stabilize the membrane.



6 Healing at six months.

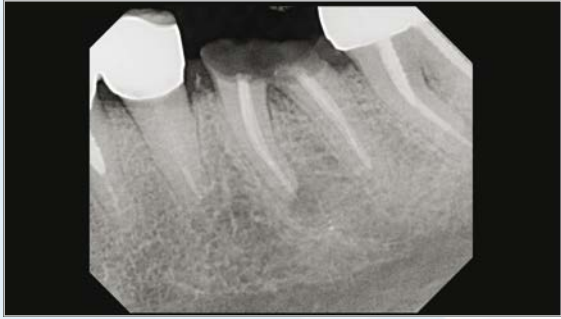

7 *Zimmer Tapered Screw-Vent* implant placed without flap.

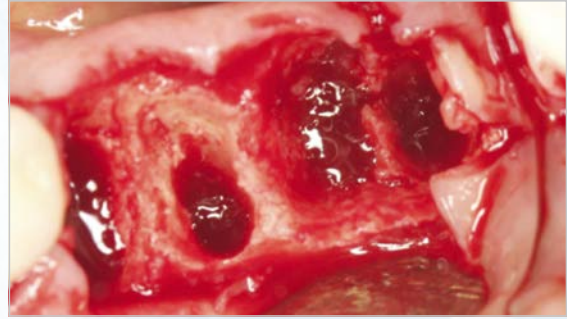


8 Post-operative radiograph four month after the *Zimmer Tapered Screw-Vent* implant placement.

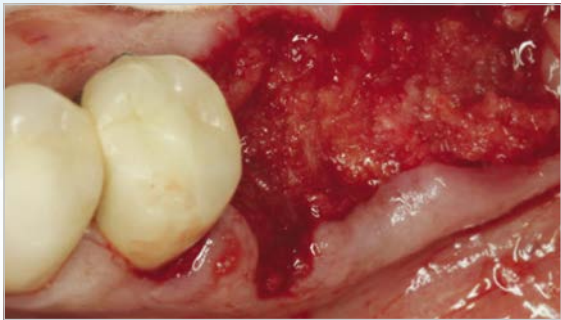
CASE #2: CopiOs Extend Membrane with Puros DBM Putty with Chips: Mandibular Molar



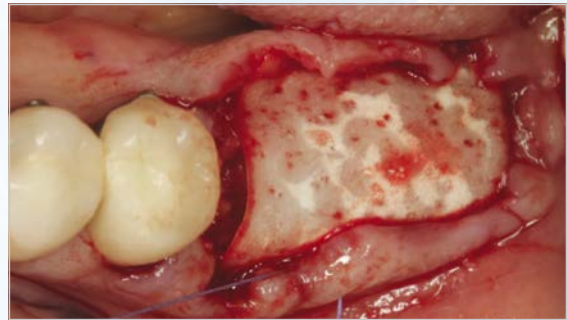
1 Pre-operative radiograph revealing fractured molars.



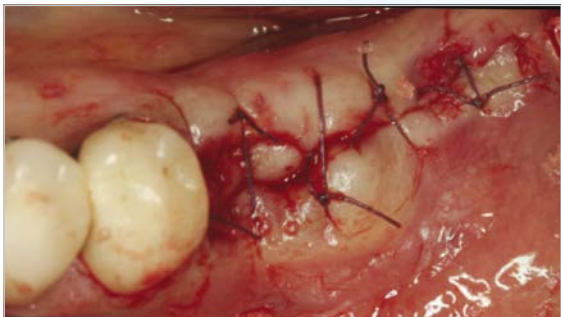
2 Surgical site after extraction exhibiting substantial bone loss on the buccal wall of mandibular molars.



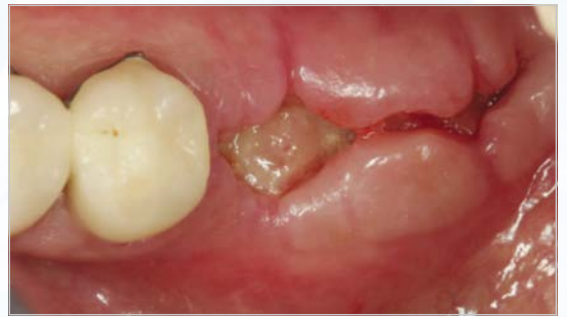3 *Puros DBM Putty with Chips* molded in place.



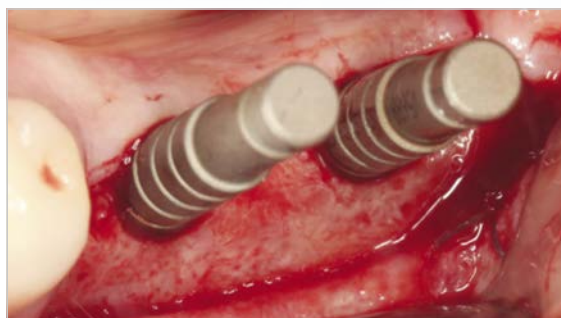
4 *CopiOs Extend Membrane* placed over the graft and stabilized by the flap.



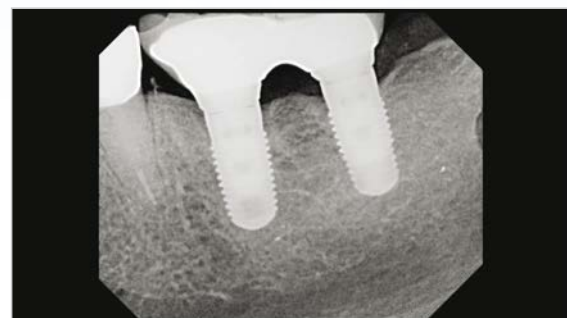5 Flap sutured



6 Two weeks post-operative image.

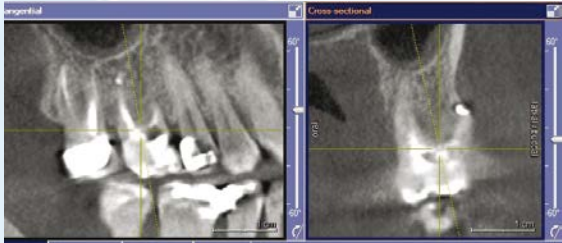

7 Site preparation at 6 months to receive two *Zimmer Tapered Screw-Vent* implants.

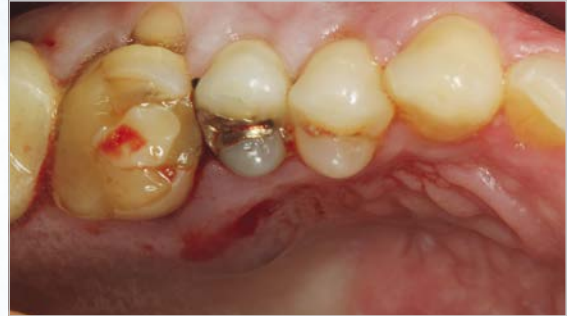

8 Radiograph of implants one year post loading.

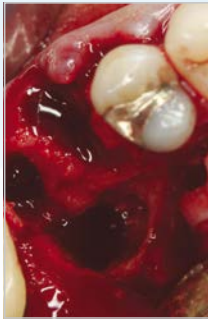CASE #3: CopiOs Extend Membrane with Puros DBM Putty with Chips: Maxillary Molar



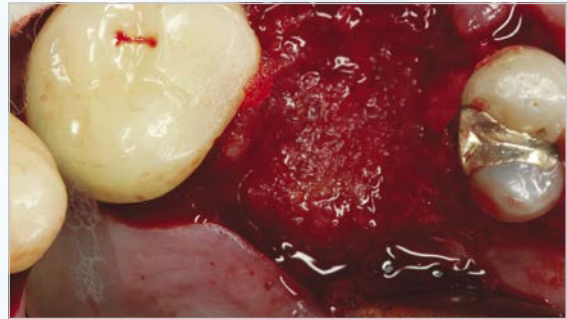
1 Pre-operative CBCT showing the extensive bone loss mostly on the palatal root.



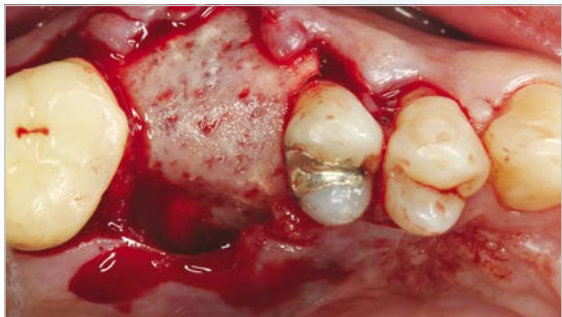2 Clinical image showing the palatal abscess.



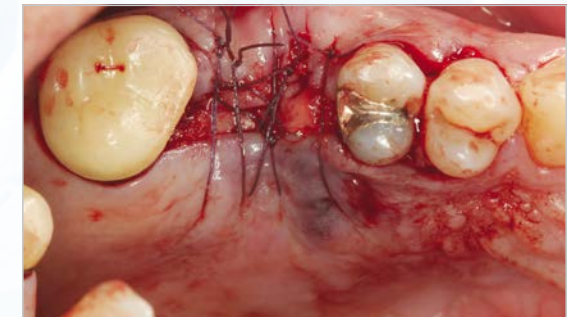3 Clinical image showing the extensive bone loss on the palatal area extending past apex.



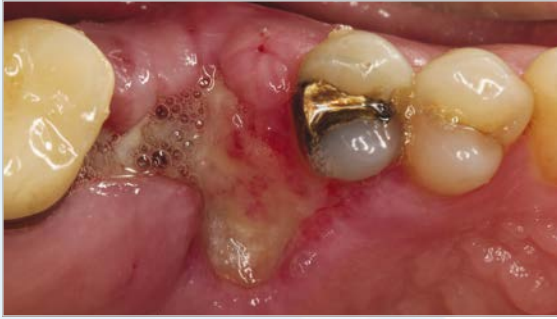4 *Puros DBM Putty with Chips* was molded in the area.



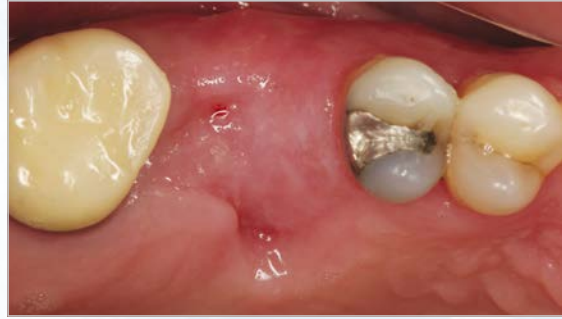5 *CopiOs Extend Membrane* was layed over the graft and tucked under the flap.



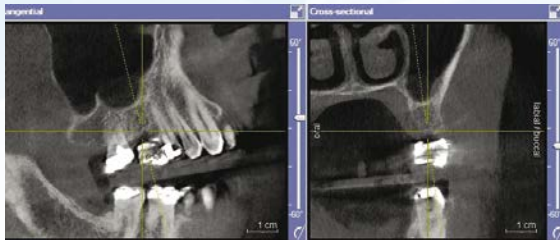6 Flap sutured over the membrane.



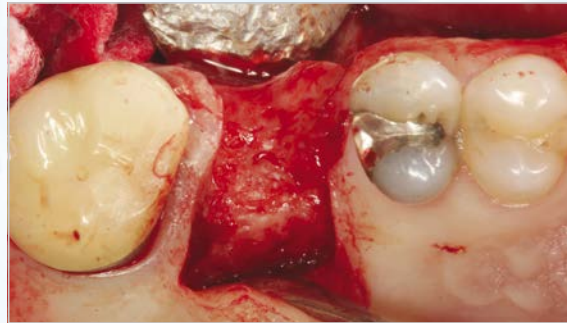
7 One-week post-operative.



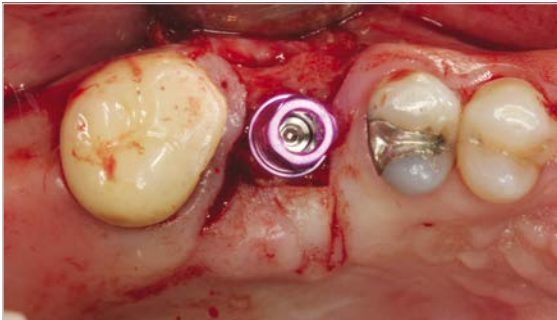
8 Two-month post-operative.



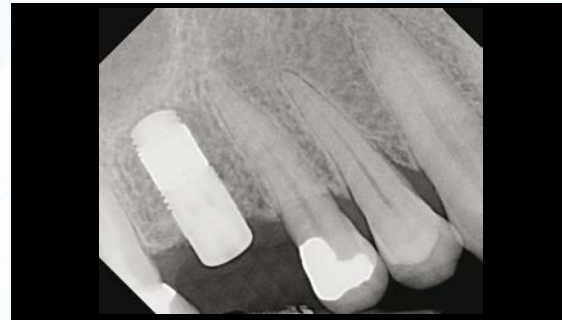9 Six-month CBCT scan showing the bone regenerated in the grafted site.



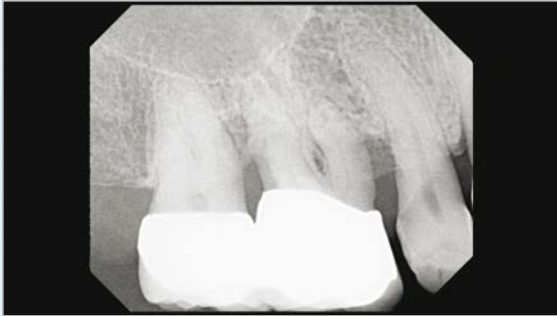10 Clinical view of grafted site at 6 months with flap raised for implant placement.



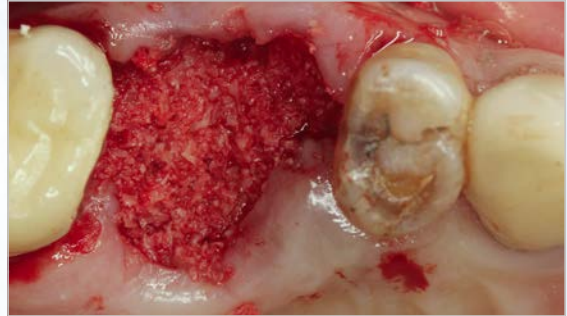
11 Zimmer Trabecular Metal™ Dental Implant in place.



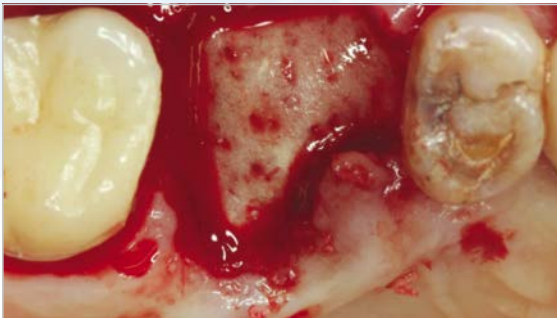
12 Post-operative radiograph of Zimmer Trabecular Metal Dental Implant in place.

CASE #4:**CopiOs Extend Membrane with
Puros Cortico-Cancellous Allograft: Maxillary Molar**

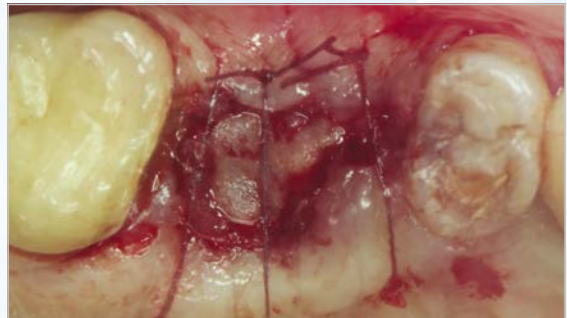
1 Pre-operative radiograph showing the poor periodontal prognosis.



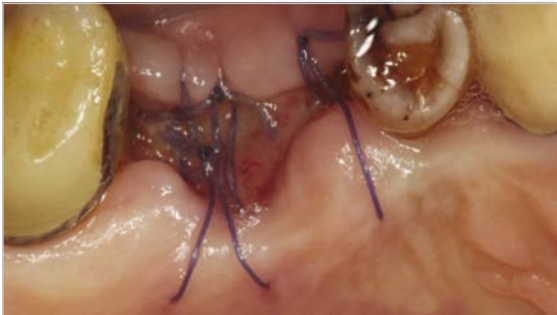2 Puros Allograft placed in the socket.



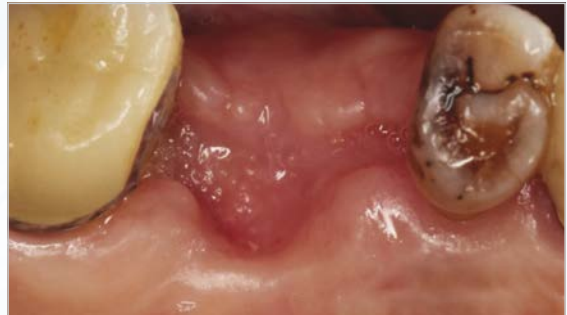
3 CopiOs Extend Membrane tucked under the flap over the graft.



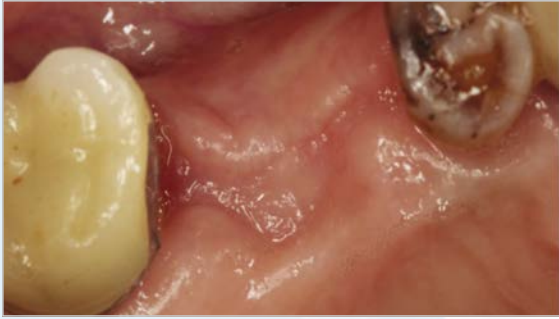4 Sutures secure the membrane.



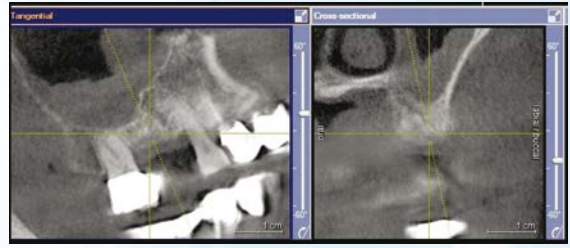5 Two weeks post-operative.



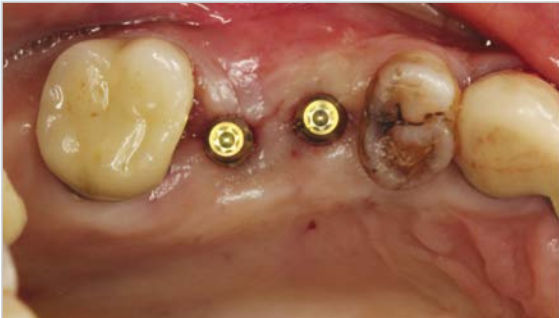6 One month post-operative.



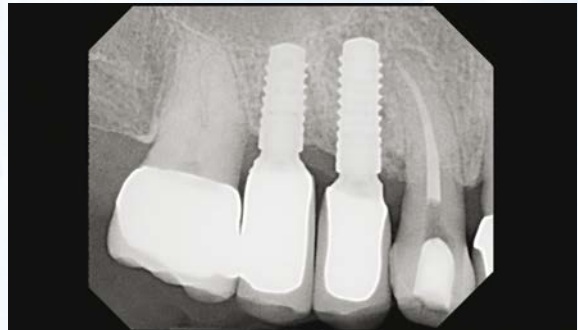7 Six month post-operative.



8 A CBCT image before implant placement showing adequate bone regeneration at the site.

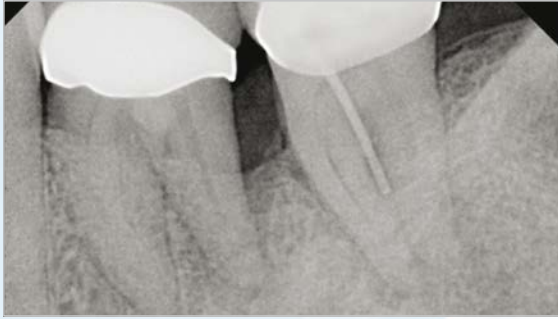

9 Two 3mm small diameter implants placed.

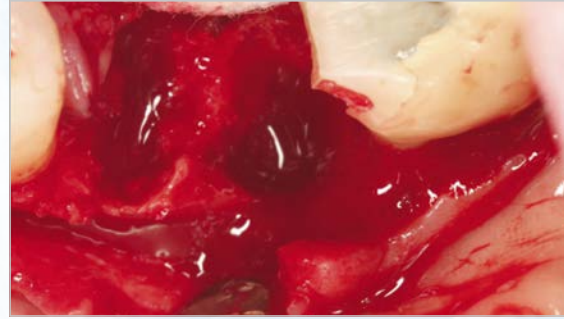


10 Two years post-operative radiograph.

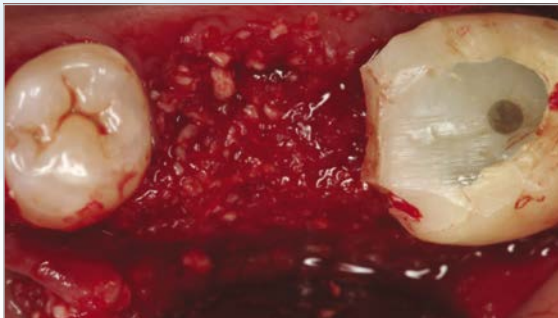CASE #5: CopiOs Extend Membrane with Puros DBM Putty with Chips: Mandibular Molar



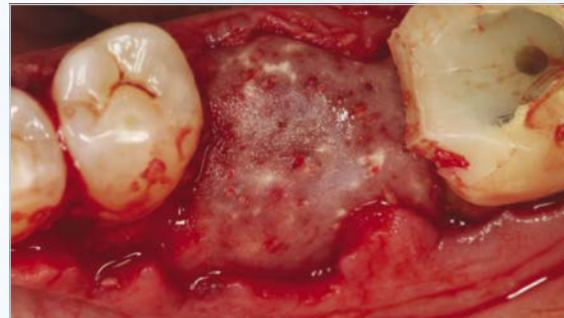
1 Pre-operative radiograph showing the perio-endodontic lesion around the distal root of 1st molar.



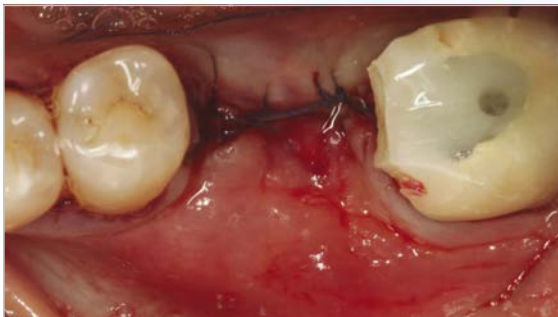2 Surgical site after extraction exhibiting a substantial bone loss on the disto-buccal wall of 1st molar and mesial root of 2nd molar.



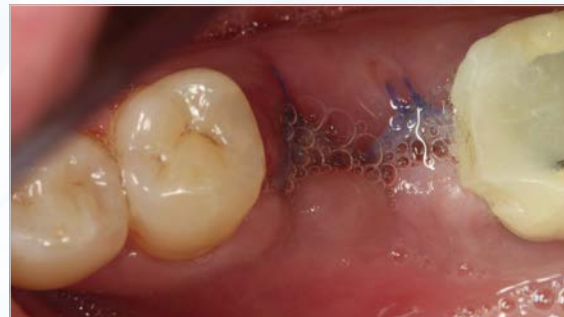3 Puros DBM Putty with Chips molded in place.



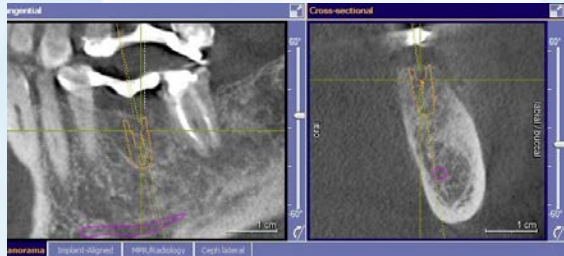4 CopiOs Extend Membrane laid over the graft and stabilized by the flap and a tack on the buccal.



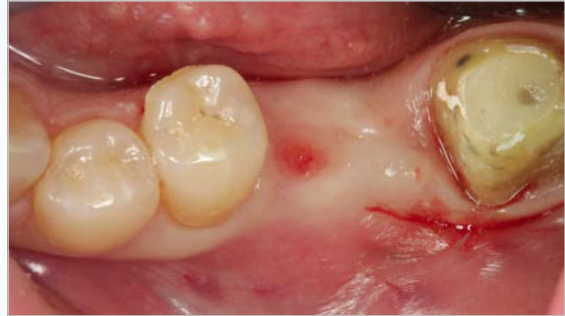5 Flap sutured.



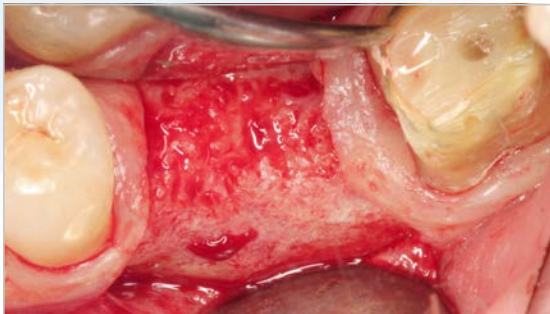
6 One week post-operative.



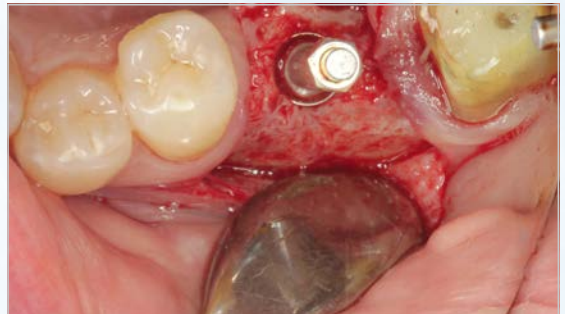
7 Six month post-operative CBCT image prior to implant placement showing adequate regeneration.



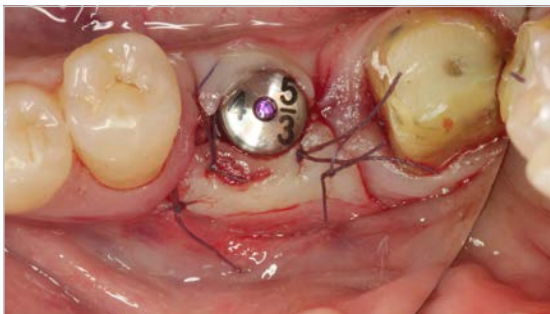8 Six month post-operative image.



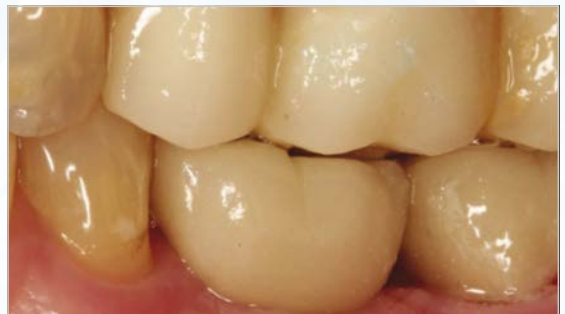9 Clinical image of the site regenerated.



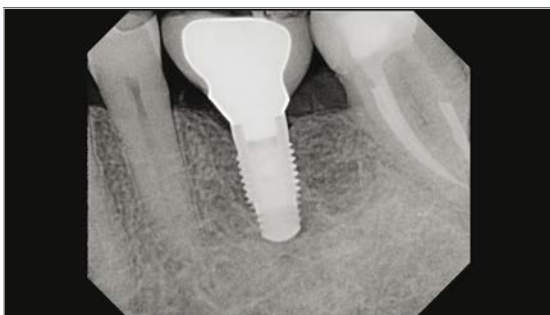10 Site preparation to receive a *Zimmer Tapered Screw-Vent* implant.



11 Flap sutured around the healing abutments. Implant stability was sufficient for a single-stage procedure.



12 Picture of final restoration at 1 year post-operative.



13 Radiograph of implants one year post loading.

For more information about our Products, Regenerative Materials and Educational Opportunities, contact us:

1900 Aston Avenue
Carlsbad, CA 92008-7308
USA

In the U.S. 1 (800) 854-7019
To fax an order 1 (888) 225-2483
Outside the U.S. +1 (760) 929-4300
Australia +61 (0)2 9950 5434 or 1 (800) 241 916
Canada + 1 (905) 567-2073 or 1 (800) 265-0968
Chile +562 231 5185

China +86 21 22115147
France +33 (0)1 45 12 35 35
Germany +49 (0)761 1 56 47 0
Israel +972 (0)3 6124242
Italy +39 0438 37681
Spain +34 93 846 05 43



Zimmer Dental
1900 Aston Avenue
Carlsbad, CA 92008-7308
USA

www.zimmerdental.com

©2013 Zimmer Dental Inc. All rights reserved. ZD1191, Rev. 9/13. Puros Allografts are manufactured by RTI Biologics, Inc. and marketed by Zimmer Dental Inc. CopiOs Extend Membrane is manufactured by Collagen Matrix, Inc., and is distributed by Zimmer Dental, Inc. Please note that not all products and regenerative materials are registered or available in every country/region and Puros part numbers may vary. Please check with a Zimmer Dental representative for availability and additional information.